

Korespondensi paper dengan Judul :

Penulis : Rika Rosnelly, Bob Subhan Riza, Linda Wahyuni, Suparni Suparni, Annas Prasetio, Robbi Rahim

The screenshot shows a Gmail interface on a desktop browser. The browser tabs include '(60) WhatsApp' and 'New Submission - rikaosnelly@...'. The address bar shows a mail.google.com URL. The Gmail search bar contains 'Telusuri email'. The left sidebar shows the 'Kotak Masuk' (Inbox) with 2,312 items, and other folders like 'Berbintang', 'Draf', and 'Selengkapnya'. The main content area displays an email from 'Rika Rosnelly (Universitas Potensi Utama)' with the subject 'New Submission'. The email body contains the following text:

Dear TEM Editor,

With this email I attach an article from the results of my research in the field of computer science and I submit it to the TEM Journal. I hope my article can be published in your journal. Thank you.

Best regards
Rika Rosnelly

Below the text, there is a virus-free notification from Avast and a Microsoft Word attachment icon labeled '15122021-01 Rika...'. The Windows taskbar at the bottom shows the system tray with a temperature of 30°C, location 'Berawan', and the time 11:17.

Korespondensi paper dengan Judul :

Penulis : Rika Rosnelly, Bob Subhan Riza, Linda Wahyuni, Suparni Suparni, Annas Prasetyo, Robbi Rahim

This screenshot shows a Gmail inbox on a Windows desktop. The browser tabs include WhatsApp, a new submission page for 'rikarosnelly@', and Google Translate. The email address in the address bar is 'mail.google.com/mail/u/0/?tab=rm&ogbl#inbox/QgrcHsbhNVcNZHPHQVKTwnVKKPsfNwcdV'. The Gmail interface shows a search bar with 'Telusuri email' and a 'Tulis' button. The left sidebar lists folders: Kotak Masuk (2.312), Berbintang, Ditunda, Terkirim, Draft (53), and Selengkapnya. The main content area displays an email from 'TEM Journal' (igwat@gmail.com) dated '7 Feb 2022 01.37 (4 hari yang lalu)'. The email text reads: 'Dear Rika Rosnelly, The paper originality is acceptable. We are sending you originality report of the text. Your work is currently in process of review, and it will be finished as soon as possible. Best Regards, Editorial Board office. www.temjournal.com office@temjournal.com temjournal@gmail.com'. A PDF attachment is visible with the title 'Improvement of Hybrid Image Enhancement for Detection and IT Report 92%.pdf'. The Windows taskbar at the bottom shows the date as 11:24 and temperature as 29°C.

This screenshot shows a Gmail inbox on a Windows desktop, similar to the first one. The browser tabs are the same. The email address in the address bar is 'mail.google.com/mail/u/0/?tab=rm&ogbl#inbox/QgrcHsbhNVcNZHPHQVKTwnVKKPsfNwcdV'. The Gmail interface is consistent. The left sidebar shows the same folder list. The main content area displays a reply email from 'Rika Rosnelly (Universitas Potensi Utama)' (rikarosnelly@gmail.com) dated '10 Feb 2022 12.28 (22 jam yang lalu)'. The email text reads: 'Dear TEM Editor, With this email I have attached a correction article. Thank you. Best Regards'. A PDF attachment is visible with the title 'For example.pdf'. At the bottom of the email, there are buttons for 'Balas' and 'Teruskan'. The Windows taskbar at the bottom shows the date as 11:26 and temperature as 29°C.

Korespondensi paper dengan Judul :

Penulis : Rika Rosnelly, Bob Subhan Riza, Linda Wahyuni, Suparni Suparni, Annas Prasetio, Robbi Rahim

This screenshot shows a Gmail inbox with the search filter 'in:trash'. The selected email is titled 'New Submission' and is marked as 'Sampah' (spam). It was sent from Rika Rosnelly (Universitas Potensi Utama) to the TEM Journal office on Wednesday, December 15, 2021, at 18:28. The email content includes a greeting to the TEM Editor, a statement of intent to submit a research article in computer science, and a sign-off with 'Best regards, Rika Rosnelly'. A virus-free notification from Avast is visible at the bottom of the email body.

This screenshot shows a Gmail inbox with the search filter 'in:trash'. The selected email is a response from the TEM Journal office to Rika Rosnelly, dated Tuesday, February 7, 2022, at 01:37. The email content states that the paper's originality is acceptable, an originality report is being sent, and the work is currently under review. It concludes with 'Best Regards' and contact information for the Editorial Board office, including the website www.temjournal.com, the office email office@temjournal.com, and the journal's email temjournal@gmail.com. A PDF attachment titled 'Improvement of Hybrid Image Enhancement for Detection and IT Report 92%.pdf' is visible at the bottom of the email body.

Improvement of Hybrid Image Enhancement for Detection and Classification of Malaria Disease Types and Stages with Artificial Intelligence

Rika Rosnelly¹, Bob Subhan Riza², Linda Wahyuni³, Suparni Suparni⁴, Annas Prasetyo⁵, Robbi Rahim⁶

^{1,2,3,5}Faculty of Engineering and Computer Science, University of Potensi Utama, Medan, Indonesia

⁴Health Faculty, Politeknik Kesehatan Kementerian Kesehatan Medan, Medan, Indonesia

⁶Faculty of Engineering Technology, Universiti Malaysia Perlis, Pauh, Malaysia

rikarosnelly@gmail.com¹, bob.potensi@gmail.com², linda@potensi-utama.ac.id³, hajjahsuparni@gmail.com⁴, annasprasetyo45@gmail.com⁵, robbirahim@ieee.org⁶

Formatted: Font: 22 pt

Abstract. Malaria is an infectious disease throughout the world where the disease is transmitted by infected female Anopheles mosquitoes. Malaria has some symptoms that are almost like ~~eovid~~COVID-19. Malaria has several other symptoms, characterized by chills, anemia, cold sweats, nausea and vomiting, and a sudden drop in blood pressure. Identification of the type of malaria begins with preprocessing, feature extraction, and classification for identification. Image improvement is part of the preprocessing stage to improve image quality so that the malaria parasite object in the image can be seen clearly. This study tries to improve the algorithm with hybrid dark and contrast stretching. Performance evaluation of malaria parasite image improvement using Mean Square Error (MSE) and Peak Signal Noise Ratio (PSNR). The results obtained with the improvement of dark hybrids and contrast stretching can improve the image quality of malaria parasite objects with MSE value = 0.0095 and PSNR value = 22.8404, compared with dark stretching, contrast stretching, histogram equalization.

Keywords: Artificial Intelligence, Malaria, Dark Stretching, Contrast stretching, histogram equalization, and dark and contrast stretching.

1. Introduction

Malaria is an infectious disease that occurs all over the world, especially in tropical climates. The Ministry of Health said that data on malaria cases is still difficult to eliminate because several regions have not succeeded in eliminating any of these malaria cases, such as in Papua, Maluku, and

West Papua. Director of Prevention and Control of Vector and Zoonotic Diseases of the Ministry of Health Didik Budijianto explained that finding malaria cases is a challenge, especially during the COVID-19 pandemic[1]. Factors causing malaria are knowledge and attitudes of the community towards malaria. Infections caused by ~~m~~Malaria can cause death, especially in high-risk groups such as pregnant women, infants, children under five. Malaria has symptoms that are almost like COVID-19 which are characterized by clinical symptoms, namely fever, chills, anemia, cold sweat, nausea and vomiting, and a sudden drop in blood pressure [1, 2]. Malaria is caused by the Plasmodium parasite and spread by a female Anopheles mosquito bite. Human Plasmodium falciparum, vivax, malaria, and oval [3].

Some standard tests are carried out by experts to identify malaria, using microscopic tools, ~~which ant it takes~~ a long time which require a laboratory to get the type of parasite and its stage. We need a system that can make it easy to identify the type of malaria parasite and its stage. Several stages will be carried out for image identification for the type of malaria, starting with the preprocessing stage, feature extraction, and classification for identification. The image improvement stage is part of the preprocessing stage where this stage is the main priority because if the malaria parasite image has good image quality, then for the next stage it can produce good results so that it will produce a high accuracy value.

Several studies using thick and thin blood smears for malaria detection have improved image quality. Sabir [4] using image brightness by increasing or decreasing a constant for each pixel in

Formatted: Font: 10 pt

the image so that the histogram shifts in the application of the malaria parasite. Salamah [5] claims that enhancement of thick blood was achieved by contrast and edge correction. Contrast correction is accomplished by combining global and local contrast correction techniques, namely Dark Stretching and Contrast Limited Adaptive Histogram Equalization (CLAHE). While the edge correction algorithm employs Unsharp Masking Filtering (UMF) to smooth the edges of objects in microscopic images of malaria patients. Rakshit [6] used Sobel and Harris corner point detection to detect blood images with several forms of plasmodium, namely ring, trophozoite, merozoite, schizont. Khatkar [7] conducted biomedical image research using SIFT as well as D'Mayer and Coiefflet wavelets to improve image quality. Hanif [8] used dark stretching on thick blood images, Nasir [9] used linear contrast stretching and modification of thin blood smears. According to Das [10], to increase the contrast of thick blood smears, illumination correction was performed using the red and blue channels by multiplying the intensity of each channel by the appropriate gain using a combination of gaussian low pass filtering, adaptive histogram equalization, and the h-minima transform. To improve the quality of thin blood smear images, this study uses a hybrid image improvement method. MSE and PSNR values were

used to evaluate the performance of a malaria parasite image improvement method. The greater the MSE value, the poorer the display on the resulting image. In contrast, the lower the MSE value, the better the display on the resulting image. The higher the PSNR value, the better the image display results obtained after image repair. The lower the PSNR value, on the other hand, the worse the results obtained in the image repair result. MSE and PSNR have an inverse relationship; the higher the PSNR value, the lower the MSE value [11].

Formatted: Font: 11 pt
Formatted: Font: 11 pt

2. Research Methodology

This image quality improvement research uses several stages, where the malaria parasite image data obtained is primary data, originating from the Health Laboratory of North Sumatra Province and photographed using a digital microscope at the Health Polytechnic of North Sumatra. The image of the malaria parasite with four species, namely falciparum, vivax, malaria, and ovale, and for each species has four stages, namely ring, trophozoite, schizont, gametocyte. The image data infected with malaria amounted to 402 images consisting of 4 types of malaria parasites with 4 stages. The proposed system design can be seen in Figure 1.

Commented:
The novelty of this study is described in detail

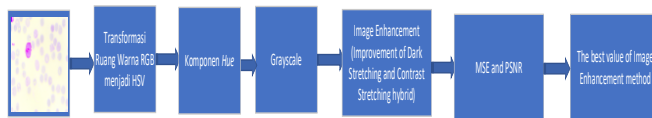


Figure 1. Design model for improvement malaria parasite image enhancement methods

Figure 1. This is a design model for developing a malaria parasite image enhancement method and few process.

2.1 Image data acquisition

At this stage, we present is the collection of malaria parasite image data. Starting with data on malaria parasite preparations sourced from the North Sumatra Provincial Health Laboratory, which was already contained in the preparations that had been given Giemsa staining. Furthermore, it is dripped with immersion oil, where the immersion oil serves to sharpen or clarify objects. Then the image is taken, where the image is taken using a digital microscope with a magnification of 1000 times. The

image can be seen on the monitor screen were in the image-taking process, accompanied by Health Laboratory officers to be able to find out the object, especially the type of malaria parasite. The types of malaria parasites used consisted of four types of malaria parasites namely vivax, ovale, falciparum, malaria and each type of malaria parasite had four stages, namely ring, trophozoite, schizont, gametocyte. Pictures of the types of malaria parasites and their stages can be seen in Figure 1.

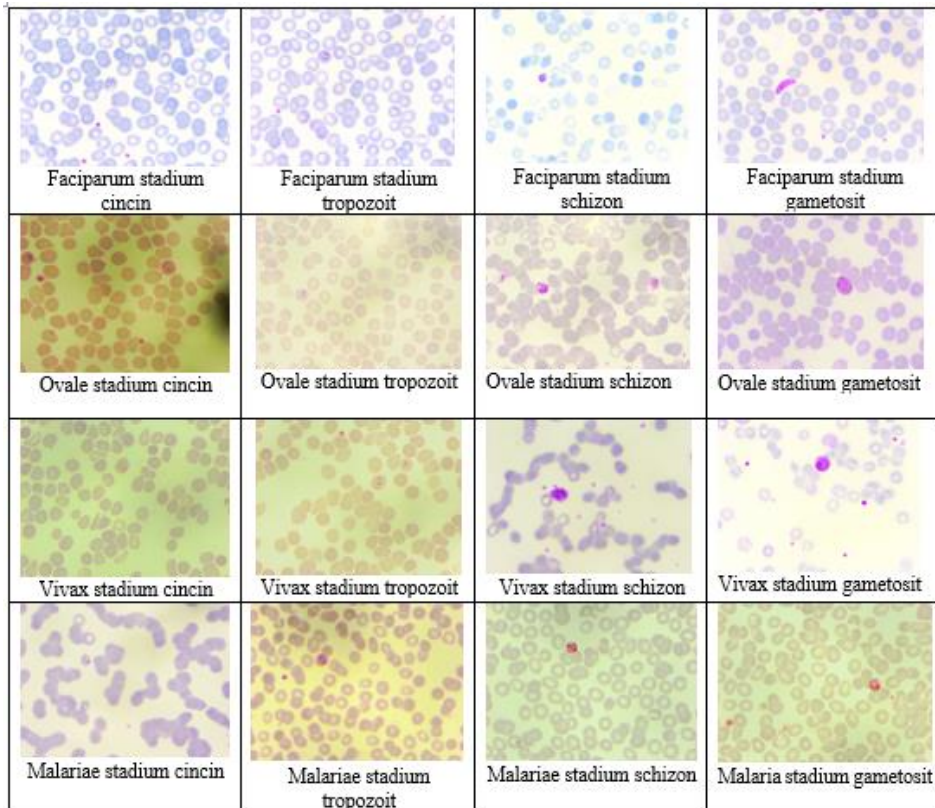


Figure 2. Image of Malaria Parasites Falciparum, Ovale, Vivax, Malariae with four stages

Figure 2- shows the image of malaria parasites falciparum, ovale, vivax, malaria with ring stage, trophozoites, schizonts, gametocytes. At the ring stage, it can be seen from its shape, which is ring-shaped and looks smooth and thin. This ring shape usually has one or two chromatin. There is usually no enlargement of the infected red blood cells but in ring-staged vivax malaria, the infected red blood cells are often larger than the infected red blood cells. In ovale malaria parasites, vacuoles are often seen.

The trophozoite stage, in the falciparum malaria parasite, does not appear to have changed shape, which is a ring-like shape but is thicker and denser. The amount of chromatin pigment may also increase and have a dense, amoeboid shape. There is a Schaffner point, the pigment tends to be smooth

and brown. Infected red blood cells are usually larger than uninfected red blood cells. In this type of malaria parasite, malaria has a characteristic that is ribbon-shaped, chromatin is round and the cytoplasm is usually dense without vacuoles. The pigment is usually rough. In the malaria parasite ovale, the pink core is dilated and James's spots are seen in large numbers and rough.

At the schizont stage, the falciparum malaria parasite contains merozoites. In mature schizonts, it usually accounts for about 2/3 of the infected red blood cells. In schizont stage vivax malaria there are merozoites, each containing a chromatin dot. At this stage, the infected red blood cells become larger. The malaria parasite malaria contains merozoites, often arranged in irregular clusters. In the ovale malaria parasite, the nucleus is slightly larger and each nucleus is followed by the cytoplasm.

At the gametocyte stage, the falciparum malaria parasite is usually crescent-shaped. The cytoplasm is usually darker (female macrogametocytes), bluer, the cytoplasm of microgametocytes (male) is usually paler. **H** **V**ivax malaria; is usually spherical and fills the host cell. Infected red blood cells are usually larger than normal red blood cells. The cytoplasm is dark blue and contains brown pigment. Scuffner's point can be seen with proper staining. In malaria, there is no enlargement of infected red blood cells. The cytoplasm is blue and chromatin is red. In malaria, the ovale is round and sometimes looks like James bit.

$$H = \begin{cases} \theta & \text{if } B \leq G \\ 360 - \theta & \text{if } B > G \end{cases} \quad (1)$$

$$= \cos^{-1} \left\{ \frac{\frac{1}{2}[(R-G)+(R-B)]}{[(R-G)^2 + (R-B)(G-B)]^{1/2}} \right\} \quad (2)$$

$$S = \begin{cases} 0 & \text{if } R = G + B \\ 1 - \frac{3}{(R+G+B)} [\min(R, G, B)] & \text{other} \end{cases} \quad (3)$$

$$V = \frac{1}{3} (R + G + B) \quad (4)$$

2.3 Transforming Hue component to Grayscale

Furthermore, the Hue component is converted to grayscale which will then be used to improve the image of the malaria parasite.

2.4 Image repair

In the image of the malaria parasite, there is still poor image quality, so here we use several image improvement methods to get an image that has good quality. Image improvement begins with

2.2 RGB to HSV Color Space Transformation

After taking the malaria parasite image, the next step is to transform the HSV (Hue Saturation Value) color space, starting from converting the RGB (Red Green Blue) color space to HSV. Hue is the actual color, Saturation is the purity of the color, Value is the brightness of the color. The advantage of using the HSV color space is that several colors are the same as those captured by the human senses. HSV image formulation can be seen in equations 1 to 4 [12], [13].

calling the image from the grayscale image. This study analyzes the image improvement methods of histogram equalization, dark stretching, contrast stretching, and hybrid dark stretching with contrast stretching to get better image quality results.

Contrast stretching is part of the image improvement process that is point processing, meaning that this process depends on the intensity value of one pixel only, not on other pixels around it [14]. The contrast stretching function can be seen in Figure 2 [15].

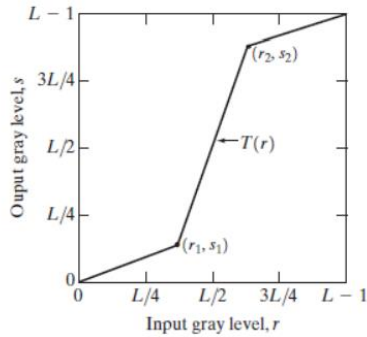


Figure 3. Contrast stretching function

In Figure 3, there is a change of the pixel contrast value from the original pixel, namely:

1. If the gray level is r_1 and r_2 and s_1 and s_2 the pixel contrast changes.
2. If $r_1=r_2$ and $s_1=s_2$, the pixel contrast does not change.
3. Image thresholding if $r_1 = r_2$ and $s_1 = 0$ and $s_2 = 255$.

Histogram equalization (HE) is a popular image improvement technique that can be used to flatten histograms. HE can provide a larger difference in pixels so that the information in the

image can be captured by the eye. The HE technique is divided into two categories, namely the global histogram method and the local histogram method [16]. Histogram alignment is obtained by changing the gray degree of a pixel (r) with a new gray degree (s) with the transformation function T , namely $s = T(r)$. The meaning is that r can be recovered from s by the inverse transformation $r = T^{-1}(s)$, where $0 \leq s \leq L-1$. The main target of histogram alignment is to obtain histogram equalization so that the degree of gray has a relatively equal number of pixels. The histogram alignment equation can be seen in equation 5 [17], [18].

$$p_r(r_k) = \frac{n_k}{n} \text{ dalam hal ini } r_k = \frac{k}{L-1}, 0 \leq k \leq L-1. \quad (5)$$

Where the gray degree (k) is normalized to the largest gray degree ($L-1$). The value of $r_k = 0$ represents black, and $r_k = 1$ represents white on a grayscale.

Dark Stretching is a technique that uses auto-scaling, a linear mapping function, to increase an

image's brightness and contrast. The dark stretching technique uses the image's original brightness and contrast levels to adjust. Equations 6 and 7 show the dark and contrast stretching formulation [19], [20].

$$I'(a, b) = \begin{cases} \frac{I(a, b)}{Th} \times \text{new Th} & ; \text{for } I(a, b) < Th \\ \left[\left(\frac{I(a, b) - Th}{255 - Th} \right) \times (255 - \text{new Th}) \right] + \text{new Th} & ; \text{for } I(a, b) > Th \end{cases} \quad (6)$$

$$I'(a, b) = \begin{cases} \frac{I(a, b) - Th}{255 - Th} \times \text{new Th} & ; \text{for } I(a, b) < Th \\ \left[\left(\frac{I(a, b) - Th}{255 - Th} \right) \times (255 - \text{new Th}) \right] & ; \text{for } I(a, b) > Th \end{cases} \quad (7)$$

The output and input pixel intensities are $I'(a, b)$. The stretching factor is new Th . The dark stretching

process tends to stretch values above the threshold. Figure 4 depicts dark and contrast stretching.

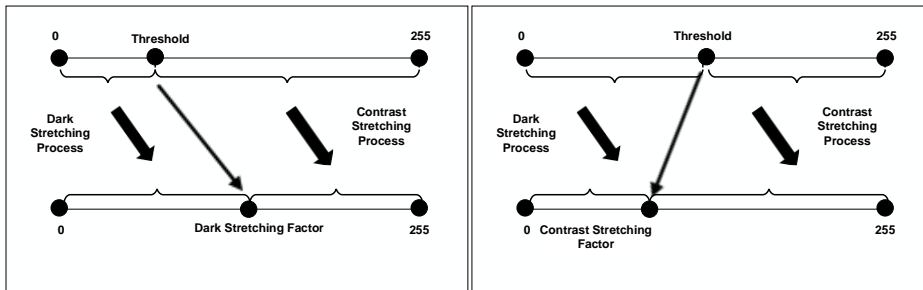


Figure 4. Dark Stretching dan Contrast Stretching Process

Figure 4 shows the hybrid process of dark and contrast stretching methods by providing a new threshold which is a stretching factor. The development which is a novelty in this research is the development of an image improvement method using a hybrid of dark and contrast

stretching methods as well as algorithm improvement on dark and contrast stretching by increasing constant values. The development of a hybrid algorithm for the dark and contrast stretching methods can be seen in Figure 5.

- Formatted: Font: 11 pt
- Formatted: Font: 11 pt, Not Bold
- Formatted: Font: 11 pt
- Formatted: Font: 11 pt
- Formatted: Font: 11 pt, Not Bold
- Formatted: Font: 11 pt
- Formatted: Font: 11 pt

```

Dark Stretching and Contrast Stretching Algorithm
1. Call the HSV color space transformed image : Hue
2. Determine the pixel intensity (dark stretching):
   Img_adj = imadjust(Img_Hue, [graythresh(Img_Hue) 1])
3. Determine the level of gray level spread and increasing a constant value
   (contrast stretching)
   Img_adj = 0.1 + imadjust(Img_adj);
4. Save as dark and contrast stretching image
5. Repeat Steps 1 to 5, for other images
6. Finish
  
```

Figure 5. Improvement of Hybrid algorithm of dark and contrast stretching method

Formatted: Font: Not Bold

2.5 Performance Evaluation

The MSE and Peak Signal to Noise Ratio are used to evaluate image improvement performance (PSNR). It is possible to measure the image quality improvement method by comparing the final image to the original image, but it is difficult to detect abnormalities in medical images without a solid

knowledge base. The MSE is calculated by comparing the pixels of the original image to the resultant image at the same pixel position. The PSNR is the maximum strength of the image signal to noise, which affects the representation accuracy [21], [22]. Equations 8 and 9 show the two performance measures.

$$MSE = \frac{1}{AB} \sum_{x=1}^A \sum_{y=1}^B (g(x, y) - f(x, y))^2 \quad (8)$$

where $g(x, y)$ is the image before the image repair and $f(x, y)$ is the image after repair.

$$PSNR = 10 \log_{10} \left(\frac{(\text{Max } I^2)}{MSE} \right) \quad (9)$$

3. Results and Discussion

The parasite images used are 402 images of malaria parasites with four types of malaria parasites where

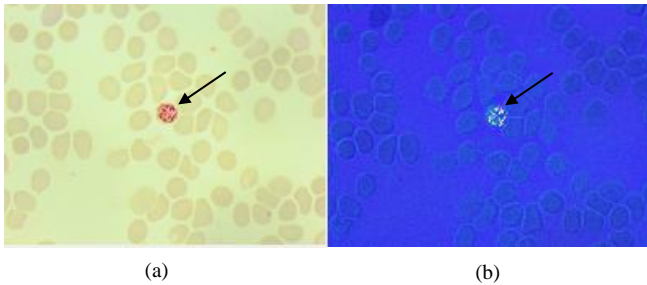


Figure 6. Example of the color space transformation of the malaria parasite image (a) RGB image, (b) Image converted from RGB to HSV

Figure 6(a): shows an RGB image, then it is converted to HSV (b). Transformation of RGB color space into HSV can be assumed coordinates R, G, B (0 or 1) which is a sequence of red, green, blue colors in the RGB color space, max is the maximum value of the value (red, green, blue), min is the value minimum of values (red, green, blue). After converting the color space to HSV, what is used in the next stage is the Hue component,

each type of parasite consists of four stages with a size of 2592 x 1944 pixels. An example of HSV color results for malaria parasite images can be seen in Figure 6.

because the three HSV components are visually able to distinguish between objects and the background is the hue component where the hue component is obtained from the HSV image.

Based on equation 1: the results of the image of the malaria parasite transforming the HSV color space, namely the Hue component, can be seen in Figure 7.

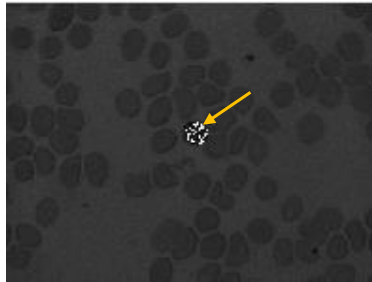


Figure 7. Example of the image of the malaria parasite transforming the HSV color space, namely the Hue component

Figure 7: is the result of the image of the malaria parasite transforming the HSV color space, namely the Hue component. In the picture, it can be seen that the parasite object has been distinguished from the background.

Furthermore, the conversion to grayscale is carried out and after getting the results of the

grayscale image, it is continued to make improvements using contrast stretching, histogram equalization, dark stretching, and hybrid dark stretching and contrast stretching methods. Examples of grayscale results and 4 image improvement methods can be seen in Figure 8.

Formatted: Font: Not Bold

Formatted: Font: Not Bold

Formatted: Font: Not Bold

Formatted: Font: Not Bold

Formatted: Font: Not Bold

Formatted: Font: Not Bold

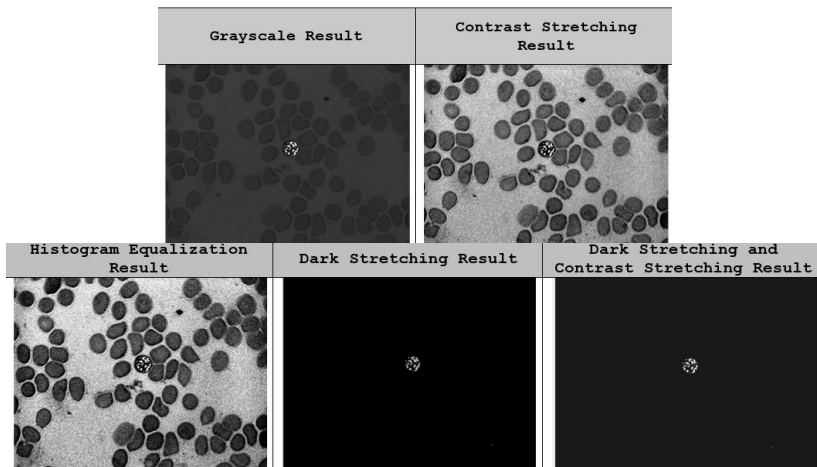


Figure 8. Example of conversion results to grayscale and 4 image improvement methods

Formatted: Font: Not Bold

Figure 8. shows a sample of the malaria parasite image converted to grayscale, from the grayscale image then image correction is carried out where the contrast stretching results can be seen to have more contrast than the grayscale results. The histogram equalization results show can be seen that the malaria parasite image has become more uniform, dark results stretching can be seen, the image increases the intensity of the image so that it distinguishes the object of the malaria parasite, as

well as the results of hybrid dark stretching and contrast stretching.

Formatted: Font: Not Bold

The results of the four image improvement methods with 402 images were evaluated using MSE and PSNR. The results of the average MSE and PSNR values using contrast stretching, histogram equalization, dark stretching, and hybrid dark stretching and contrast stretching can be seen in Table 1.

Table 1. Average MSE and PSNR values for image repair using Contrast Stretching, Histogram Equalization, Dark Stretching, and hybrid Dark Stretching & Contrast Stretching

Formatted: Font: Not Bold

Number of images	Contrast Stretching		Histogram Equalization		Dark Stretching		Dark Stretching and Contrast Stretching	
	MSE Average	PSNR Average	MSE Average	PSNR Average	MSE Average	PSNR Average	MSE Average	PSNR Average
402	0.036158	30.6815	0.083256	12.3006	0.0265	16.0495	0.0095	22.8404

Table 1. shows the average results of MSE and PSNR value using 402 images consisting of 4 types of malaria parasites namely falciparum, vivax, malaria, ovale with each having 4 stages, namely ring, trophozoite, schizont, and gametocyte. Based on Table 1, it can be seen that the results of a good image improvement method are hybrid dark

stretching and contrast stretching, which have the smallest MSE value compared to dark stretching, contrast stretching, histogram equalization. Results are obtained using dark stretching and contrast stretching with MSE value = 0.0095 and PSNR value = 22.8404.

4. Conclusion

Based on the description of the previous sections, the conclusions that can be drawn are: :

1. By using 4 methods ~~of~~for improving the image of the malaria parasite, the development of a hybrid dark and contrast stretching method has a better image quality improvement.
2. The evaluation results show that using dark and contrast stretching is better with MSE = 0.0095 and PSNR = 22.8404, while using contrast stretching shows MSE = 0.036158 and PSNR = 30.6815, histogram equalization with MSE = 0.083256 and PSNR = 12.3006, dark stretching with MSE = 0.0265 and PSNR = 16.0495. (next point) ←

References:EFERENCES

- [1] Sagita, N. S. (2021). Tampak Mirip, Ini Bedanya Gejala Corona Vs Malaria, *Detik*, 1, from <https://health.detik.com/berita-detikhealth/d-5543491/tampak-mirip-ini-bedanya-gejala-corona-vs-malaria>, accessed 11-10-2021
- [2] Indonesia, C. (n.d.). Gejala Mirip, Kenali Penanganan Malaria di Tengah Corona, from <https://www.cnnindonesia.com/gaya-hidup/20200427085517-255-497514/gejala-mirip-kenali-penanganan-malaria-di-tengah-corona>, accessed 11-10-2021
- [3] Loy, D. E.; Liu, W.; Li, Y.; Learn, G. H.; Plenderleith, L. J.; Sundararaman, S. A.; Sharp, P. M.; Hahn, B. H. (2017). Out of Africa: origins and evolution of the human malaria parasites *Plasmodium falciparum* and *Plasmodium vivax*, *International Journal for Parasitology*, Vol. 47, Nos. 2–3, 87–97. doi:10.1016/J.IJPARA.2016.05.008
- [4] Sabir, M. I. (2019). Pengaruh Image Engagement pada Aplikasi Parasit Malaria, *Jurnal Penelitian Enjiniring*, Vol. 22, No. 1, 34–37. doi:10.25042/jpe.052018.06
- [5] Salamah, U.; Sarno, R.; Arifin, A. Z.; Nugroho, A. S.; Gunawan, M.; Pragesjvara, V.; Rozi, E.; Asih, P. B. S. (2017). Enhancement of low quality thick blood smear microscopic images of malaria patients using contrast and edge corrections, *2016 International Conference on Knowledge Creation and Intelligent Computing, KCIC 2016*, 219–225. doi:10.1109/KCIC.2016.7883650
- [6] Rakshit, P.; Bhowmik, K. (2013). Detection of presence of parasites in human RBC in case of diagnosing malaria using image processing, *2013 IEEE 2nd International Conference on Image Information Processing, IEEE ICIIIP 2013*, 329–334. doi:10.1109/ICIIIP.2013.6707610
- [7] Khatkar, K.; Kumar, D. (2015). Biomedical Image Enhancement Using Wavelets, *Procedia Computer Science*, Vol. 48, 513–517. doi:10.1016/j.procs.2015.04.128
- [8] Hanif, N. S. M. M.; Mashor, M. Y.; Mohamed, Z. (2011). Image enhancement and segmentation using dark stretching technique for *Plasmodium Falciparum* for thick blood smear, *Proceedings - 2011 IEEE 7th International Colloquium on Signal Processing and Its Applications, CSPA 2011*, 257–260. doi:10.1109/CSPA.2011.5759883
- [9] Abdul-Nasir, A. S.; Mashor, M. Y.; Mohamed, Z. (2012). Modified global and modified linear contrast stretching algorithms: New colour contrast enhancement techniques for microscopic analysis of malaria slide images, *Computational and Mathematical Methods in Medicine*, Vol. 2012. doi:10.1155/2012/637360
- [10] Das, D. K.; Ghosh, M.; Pal, M.; Maiti, A. K.; Chakraborty, C. (2013). Machine learning approach for automated screening of malaria parasite using light microscopic images, *Micron*, Vol. 45, 97–106. doi:10.1016/j.micron.2012.11.002
- [11] Arco, J. E.; Górriz, J. M.; Ramírez, J.; Álvarez, I.; Puntonet, C. G. (2015). Digital image analysis for automatic enumeration of malaria parasites using morphological operations, *Expert Systems with Applications*, Vol. 42, No. 6, 3041–3047. doi:10.1016/J.ESWA.2014.11.037
- [12] Lee, S. L.; Tseng, C. C. (2017). Color image enhancement using histogram equalization method without changing hue and saturation, *2017 IEEE International Conference on Consumer Electronics - Taiwan, ICCE-TW 2017*, 305–306. doi:10.1109/ICCE-CHINA.2017.7991117
- [13] Aris, T. A.; Nasir, A. S. A.; Chin, L. C.; Jaafar, H.; Mohamed, Z. (2020). Fast k-means clustering algorithm for malaria detection in thick blood smear, *2020 IEEE 10th International Conference on System Engineering and Technology, ICSET 2020 - Proceedings*, 267–272. doi:10.1109/ICSET51301.2020.9265380
- [14] Wakhidah, N. (2011). PERBAIKAN KUALITAS CITRA MENGGUNAKAN

Commented:

In the concluding section, the next point explains the impact of evaluating the development of the hybrid dark and contrast stretching method

Formatted: Left

METODE CONTRAST STRETCHING,
Jurnal Transformatika, Vol. 8, No. 2, 78–83.
doi:10.26623/TRANSFORMATIKA.V8I2.48

- [15] Gonzalez, R. C.; Woods, R. E. (2008). *Digital Image Processing*, Prentice Hall
- [16] Mustafa, W. A.; Yazid, H. (2017). Image enhancement technique on contrast variation: A comprehensive review, *Journal of Telecommunication, Electronic and Computer Engineering*, Vol. 9, No. 3, 199–204
- [17] Jbara, W. A.; Jaafar, R. A. (2017). MRI Medical Images Enhancement based on Histogram Equalization and Adaptive Histogram Equalization, *International Journal of Computer Trends and Technology*, Vol. 50
- [18] Kaur, H.; Rani, J. (2016). MRI brain image enhancement using Histogram Equalization techniques, *Proceedings of the 2016 IEEE International Conference on Wireless Communications, Signal Processing and Networking, WiSPNET 2016*, 770–773. doi:10.1109/WISPNET.2016.7566237
- [19] Isa, N. A. M.; Mashor, M. Y.; Othman, N. H. (2003). Contrast enhancement image processing technique on segmented pap smear cytology images, *Proc. of Int. Conf. on Robotics, Vision, Information and Signal Processing*, Citeseer, 118–125
- [20] Salamah, U. (2018). Deteksi Parasit Malaria Dari Citra Mikroskopis Apusan Tebal Darah-Detection Of Malaria Parasite From Thick Blood Smear Microscopic Image, Institut Teknologi Sepuluh Nopember
- [21] Abdul Ghani, A. S.; Mat Isa, N. A. (2015). Enhancement of low quality underwater image through integrated global and local contrast correction, *Applied Soft Computing*, Vol. 37, 332–344. doi:10.1016/j.asoc.2015.08.033
- [22] Ghosh, M.; Chakraborty, C.; Konar, A.; Ray, A. K. (2014). Development of hedge operator based fuzzy divergence measure and its application in segmentation of chronic myelogenous leukocytes from microscopic image of peripheral blood smear, *Micron*, Vol. 57, 41–55. doi:10.1016/j.micron.2013.10.008